

Intracranial arachnoid cysts: special issue

Tatiana Protzenko, Alexandre Varella Giannetti

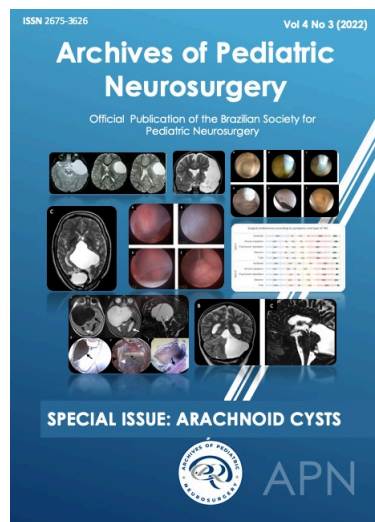
¹ Pediatric Neurosurgery Division,
Fernandes Figueira Institute, Oswaldo
Cruz Foundation (IFF-Fiocruz)

² Department of Surgery, School of
Medicine and Department of Pediatric
Neurosurgery of Hospital das Clínicas,
Federal University of Minas Gerais, Belo
Horizonte, Minas Gerais, Brazil

To whom correspondence should
be addressed: Tatiana Protzenko,
MD

e-mail: tatianaprotzenko@gmail.com

Available at:
<http://www.archpedneurosurg.com.br/>



Keywords: Arachnoid cysts, Editorial

Intracranial arachnoid cysts (AC) are arachnoid-lined expansion of the normal subarachnoid space. They are very common and neurosurgeons, specially those taking care of the pediatric population, face this disease in their daily activities quite frequently. So, considering the importance of this topic, the editorial board of Archives of Pediatric Neurosurgery decided to dedicate the present issue to articles addressing any view of AC.

The first article is an interesting and complete review of many aspects of AC that must be known by pediatric neurologists and neurosurgeons concerning epidemiology, pathophysiological, symptomatology, imaging and classification. It is well known that, frequently, AC are discovered incidentally on radiological exams. In other cases, it is difficult to establish a relationship between the symptoms and the AC. Is a headache related to the cysts? Is the seizure an effect of the cyst? In spite of the doubts regarding symptoms and AC, de Lima et al describe some clinical manifestations according to AC locations. The association and risk of developing subdural hemorrhage and AC is also discussed. And finally, the authors analyze literature data regarding a frequent and practical aspect about how to counsel parents and patients harboring an AC in the sports practice.

The knowledge of the natural history of a disease is the first step in the decision making of any patient. This is particularly important in pathological conditions that are discovered incidentally or in asymptomatic patients. Albuquerque Souza et al performed an excellent literature review on this topic that may guide us how to manage our patients. Who do we should operate? What are the cases of highest risk of cyst growing?

Regarding treatment, the literature ranges from CSF shunts to microsurgery and neuroendoscopy. In this sense, Cavalcante et al discuss the role of neuroendoscopy and the possible associated complications that can be expected. Two articles address treatment of AC at the quadrigeminal cistern and posterior fossa. Furtado et al propose a therapeutic algorithm based on a literature review and Dastoli et al describe four posterior fossa AC treated by neuroendoscopic fenestration.

In the setting of Clinical Images, da Silva et al present a suprasellar arachnoid cyst with an unusual extension to the middle fossa.

The great advantage in participate of Archives of Pediatric Neurosurgery is to be able to discover different clinical and surgical approaches, especially on controversial topics such as arachnoid cysts, around the different pediatric neurosurgery departments in our continental country. Thereby, Mansilla et al, with the honorable participation of a great friend of Brazilian pediatric neurosurgery, Gianpiero Tamburrini, share a survey that demonstrates which symptoms were considered related to AC, which complementary exams should be performed and the types of treatment chosen among Brazilian pediatric neurosurgeons. The APN editorial board invite its readers to discover these articles and delve further into the controversial topic of arachnoid cysts.