

# Wormian bones and nonsyndromic craniosynostosis: A comparative study using computed tomography

Leopoldo Mandic Furtado<sup>1</sup>, José Aloysio da Costa Val Filho<sup>1</sup>, Rayane Toledo Simas, François Dantas<sup>1</sup>, Julia Braga Holliday<sup>2</sup>, Júlia da Silva Costa<sup>2</sup>, Aieska Kellen Dantas dos Santos<sup>1</sup>

<sup>1</sup> Department of Pediatric Neurosurgery, Vila da Serra Hospital, Nova Lima, Minas Gerais, Brazil

<sup>2</sup> José Rosário Vellano University, Belo Horizonte, Brazil

To whom correspondence should be addressed: Leopoldo Mandic Ferreira Furtado, MD

e-mail: lmandicster@gmail.com

Available at: <http://www.archpedneurosurg.com.br/>

**Introduction:** Wormian bones (WB) are accessory bones positioned within the sutures or fontanelles. Although several studies have associated them with genetic disorders, ethnicity, and skull deformations, their relationship with nonsyndromic craniosynostosis (CS) has not been established, especially among Brazilians. Therefore, this study was conducted to analyze the incidence and association of WB with nonsyndromic CS in Brazilian children.

**Methods:** An observational and retrospective study was conducted using computed tomography with 3D reconstruction in Brazilian children aged <3 years to compare the incidence and number of WB between regular children (group 1) and those with nonsyndromic CS (group 2).

**Results:** A total of 140 children, comprising 62.9% boys ( $p < 0.001$ ) with a mean age of 8.78 months, were included in this study. The most common types of CS were trigonocephaly (34; 48.6%), scaphocephaly (25; 35.7%), anterior plagiocephaly (5; 7.1%), posterior plagiocephaly (3; 4.2%), and brachycephaly (3; 4.2%). WB were more common in regular children (41; 58.6%) than in children with CS (28; 40.0%) ( $p = 0.028$ ). Regular children had an average of 2.12 WB versus 1.32 WB in children with nonsyndromic CS ( $p = 0.024$ ).

**Conclusion:** The significantly less incidence of WB in Brazilian children with nonsyndromic CS was quite different from that reported in other studies and could indicate the tendency of this disease to have disturbance in ossification of the cranial vault, the impact of ethnicity, and probably the lack of additional compensatory skull growth.

**Keywords:** Wormian bones, Craniosynostosis, CT scan, Anatomym mild head trauma

## INTRODUCTION

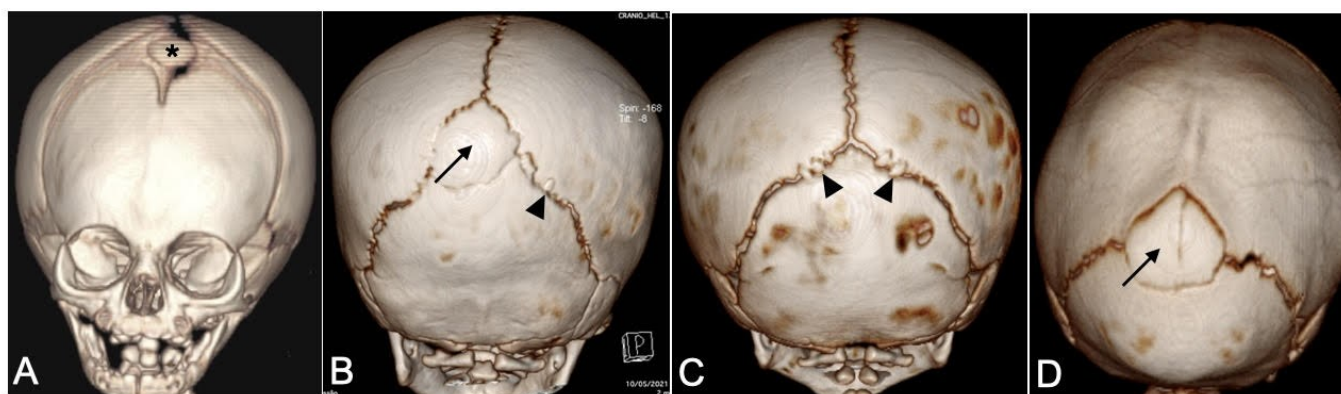
Wormian bones (WB) or intrasutural bones are isolated ossicles with variable size, thickness, and shape, which can be found in the sutures or fontanelles of the skull. They received this eponym by Thomas Bartholin to honor the Dutch anatomist Olaus Wormius [1], despite the fact that the first description of WB was attributed to Paracelsus (1460–1541), who named a bone located in the posterior fontanelle termed as “ossiculum antiepilepticum” [2, 3]. Such bones also received an interesting designation of the “Inca bone” when located in the posterior fontanelle based on observations in Peruvian mummies [4] (Figure 1).

The prevalence of WB in the general population is variable and apparently dependent on ethnicity and age, with the highest proportion ever described belonging to the Chinese population, reaching 80% of cases. Furthermore, the pediatric population presents an average rate of WB of 53% [3, 5–7]. Beyond demographic factors, genetic and skull deformities have also been considered as factors associated with the incidence of WB, and the relationship with imperfect osteogenesis has already been consolidated [8–10].

Provided that WB would represent an abnormal site of ossification and could impact skull growth, it was surmised that their presence could be altered in patients with



## Wormian bones and nonsyndromic craniosynostosis: A comparative study using computed tomography



**Figure 1-** Different types and distribution of WB are represented on the CT scan with 3D reconstruction. WB are observed on the bregma (\*) in a newborn with trigonocephaly (A) and simultaneously on the lambda termed as “Inca bone” (thin arrow) and the lambdoid suture (arrowhead) in a healthy child (B). Numerous small WB were observed in a normal child in the lambdoid suture bilaterally (C). An Inca bone is observed in a child with scaphocephaly (D).

craniosynostosis (CS). For this purpose, some studies have correlated a higher incidence of WB with nonsyndromic CS, which is a disease that progresses with the premature fusion of one or more skull sutures and affects approximately one each of two thousands of live births [11-13]. Sanchez-Lara et al [14] found that the incidence of WB is approximately 3.5 times higher in patients with CS. However, given the wide variation in the incidence of WB among the global population, it is not clear whether this correlation is reproducible. Due to this lack of knowledge, it is important to clarify the incidence of WB in Brazilian children with and without nonsyndromic CS.

Therefore, this study was conducted to evaluate the correlation between the prevalence of WB in normal Brazilian children and those with nonsyndromic CS and to describe the patterns of the position and quantity of WB.

### MATERIAL AND METHODS

#### Study design and eligibility criteria

Following the ethical board approval under the protocol (30620120.7.0000.5134), a retrospective study was designed to examine data from the medical records of patients aged <3 years and attended by the pediatric or pediatric neurosurgery at a single private hospital between January 2016 and December 2019.

For the study design, the following two primordial groups were formed: a group consisting of previously healthy children who were attended at the emergency department due to minor head trauma with indication to undergo computed tomography (CT) scan of the skull (group 1) and another group consisting of children with nonsyndromic CS who underwent surgery at the same single institution by the pediatric neurosurgery team (group 2).

The following patients were excluded from this study: those who were attended due to head trauma who presented any intracranial hemorrhages or skull fractures; patients with abnormalities not related to the trauma, such as cysts, ventriculomegaly, or brain dysmorphism; and all patients with osteogenesis imperfecta and syndromic CS such as Crouzon and Apert syndrome.

#### Data collection

The following variables were analyzed in this study: (1) demographic characteristics, (2) the type of nonsyndromic CS, and (3) the presence, position, and number of WB.

Patients' CT scans were obtained in the DICOM format and transferred to the OsiriX imaging program (OsiriX, Geneva, Switzerland) [15], which was validated using ANVISA to assure the use of medical findings. The images were evaluated by the senior author of this study who assured the normality of the brain and analyzed the surface of the skull using the 3D reconstruction images.

#### Statistical analysis

The SPSS version 20 (IBM Corp., Armonk, NY), Minitab 16 (Minitab Inc., State College, PA, USA), and Excel Office 2010 (Microsoft, Redmond, WA, USA) software were used for statistical analyses.

The significance level was set at 5% with 95% confidence intervals. Qualitative variables were analyzed using the two-proportion equality test. The mean of the incidence rates between the case and control groups was compared by the analysis of variance.

## Wormian bones and nonsyndromic craniosynostosis: A comparative study using computed tomography

### RESULTS

#### Study population

A total of 140 patients were evaluated (70 normal children and 70 children with CS). Regarding demographic analysis, the mean age of the patients was 8.78 months (1 day to 36 months) (SD = 7.76), with 62.9% of them being male ( $p < 0.001$ ). A statistical difference was noted in terms of age, with the normal group being older with a mean age of 11.06 months versus 6.53 months for the group with CS ( $p = 0.047$ ).

Concerning the distribution of the types of nonsyndromic CS, the vast majority of the study population was represented by trigonocephaly (34; 48.6%), followed by scaphocephaly (25; 35.7%). Other types included anterior plagiocephaly (5; 7.1%), posterior plagiocephaly (3; 4.2%), and brachycephaly (3; 4.2%).

#### Features of WB

Overall, WB were found in 69 (49.3%) patients ( $p = 0.392$ ), and the relative incidence rate of WB in group 2 was 40.0% (28 patients) compared with 58.6% (41 patients) in group 1 ( $p = 0.028$ ).

Regarding the quantity of WB, group 1 showed a higher incidence, with a mean value of 1.32 compared with 2.12 in group 2 ( $p = 0.024$ ). The vast majority of WB was found in the lambda "Inca bone" in group 2 or the unilateral lambdoid suture in group 1. The bregma was the most unusual site to have WB and more common in patients with trigonocephaly (Figure 1) (Table 1).

No statistical difference was observed between the types of CS in terms of WB quantity ( $p = 0.137$ ), despite a trend toward more WB in patients with trigonocephaly. Overall, WB were infrequent and less numerous than those in healthy children.

### DISCUSSION

WB are accessory cranial bones that develop from independent ossification centers within sutures and have been described in an average half of normal children [16, 17]. Similarly, in the present study, the overall incidence of WB in Brazilian healthy children was 58.6%, and the lambdoid suture was found to be the primary site of these bones under normal condition (43.9%); no WB were observed on the coronal suture. These findings were different from those observed by Marti et al [2] who reported the presence of WB along the lambdoid suture in 64% of cases but similar to those observed by Jeanty et al [16] who conducted prenatal detection of WB and observed 50% of WB along the lambdoid suture or 25% along the coronal suture [16]. However, a higher incidence of the "Inca bone" was observed in children with CS, indicating that they are more susceptible to show WB in the lambdoid suture, and especially children with trigonocephaly displayed WB on the bregma. Some reports have mentioned the bregma as well as orbits as unusual sites to find WB [18, 19]. Therefore, the presence of WB on the bregma and lambdoid suture may indicate abnormal ossification on these sites, affecting patients with impaired growth of metopic and posterior sagittal sutures, respectively.

Despite the qualitative differences concerning the position of WB in children with CS observed in the present study, another important finding was the markedly less incidence of WB in such patients than in regular children, showing an overall rate of 41%. To our knowledge, such an unexpected result could have two implications as follows: (1) the expression of ethnicity on the minor incidence of WB in Brazilian children with CS and (2) as a disease with impaired bone growth, CS has less propensity to develop an alternative ossification path to compensate for the restriction, assuming the role of WB as accessory bones. However, some authors consider WB as an anatomical variant or having a specific function in bone growth. According to Pryles et al. [7], the prevalence of congenital malformations and central nervous system abnormalities such as microcephaly and macrocephaly, hydrocephalus, CS, cerebral palsy, epilepsy, and even learning difficulties in a population of children with WB ranged from 93% to 100%, based on which they mentioned that WB were a true marker of developmental abnormalities of the central nervous system. However, no patients with central nervous system abnormality were found in the present study. Agrawal et al [19] reported that WB have been shown to develop in relation to the specific location where synostosis begins. In cases of unilateral synostosis, such as those occurring along the coronal or lambdoid sutures, there was an increased frequency of WB on the contralateral sides. In cases of midline synostosis, which begins along the metopic or

**Table 1-** Distribution of Wormian bones on the 69 children

	Inca	Bregma	Lambdoid Unilateral	Lambdoid Bilateral	Inca + Lambdoid	Total n(%)
Group 1	9	1	18	9	4	41(58.6)
Group 2	15	3	6	2	2	28(40.0)
Trigonocephaly	7	3	2	1	1	14
Scaphocephaly	7	0	1	0	0	8
Anterior Coronal	1	0	0	0	0	1
Brachycephaly	0	0	1	0	0	1
Lambdoid UC	0	0	1	1	1	3
Metopic + Coronal UC	0	0	1	0	0	1
Sum	24	4	24	11	6	69(100.0)

UC = Unilateral craniosynostosis

## Wormian bones and nonsyndromic craniosynostosis: A comparative study using computed tomography

sagittal sutures, WB were formed along the midline of the skull.

Regarding sex distribution, discrepancies have been reported in the literature, and some studies have reported increased prevalence among men [16] or no differences between sexes [14]. In the present study, a higher male prevalence was observed, with a statistical significance. However, this difference was in fact due to the relative frequencies of head trauma and CS, which are more prevalent in men. Considering this fact, a bias was observed in this result.

This study has some limitations such as the retrospective collection of data, which could have some imprecisions, and the impossibility to examine the regular population more appropriately due to some bias regarding sex distribution. However, this study has the merit of describing for the first time the difference in the distribution of WB among Brazilian children using high-quality images in a single institution, which has an adequate control of variables. Although the exact role of WB in skull growth remains a speculation and more studies would be required to clarify this topic, it is clear that the major importance of recognizing these bones in regular children is to avoid the misdiagnosis of skull fractures and exclude the pseudoclosure of the anterior fontanelle. The pediatrician must be aware of this condition and request a 3D reconstruction of CT scan to avoid unnecessary hospital admission or parents' complaint.

### CONCLUSIONS

This study demonstrated for the first time the high incidence of WB in a healthy Brazilian pediatric population, which accounted for 58.6% of cases. Moreover, these bones were less common in children with nonsyndromic CS who were younger than 3 years of age compared with similar studies conducted worldwide. This result could indicate the impact of ethnicity and the loss of compensatory skull growth observed in this type of disease. Therefore, to our knowledge, WB are not a sign of skull deformation and reveal the loss of ossification ability.

### DISCLOSURES

#### *Ethical approval*

This study was performed in line with the principles of the Declaration of Helsinki. Approval was granted by the local Ethics Committee

#### *Consent to participate*

The patient gave consent to use his information and images for research proposes.

#### *Consent for publication*

The patient gave consent to use his information and images for publication.

#### *Conflict of interest*

The authors declare no conflicts of interest with respect to the content, authorship, and/or publication of this article.

#### *Funding*

This research received no specific grant from any funding agency in the public, commercial or not-for-profit sectors

#### *Acknowledgments:*

We would like to thank Mr. Thales Henrique Ulhoa. A prominent neurosurgeon and friend who encourage this work.

### REFERENCES

1. Bellary SS, Steinberg A, Mirzayan N, et al. Wormian bones: a review. *Clinical Anatomy*. 2013 Nov;26(8):922-927. 10.1002/ca.22262
2. Marti B, Sirinelli D, Maurin L, Carpentier E. Wormian bones in a general paediatric population. *Diagnostic and Interventional Imaging*. 2013 Apr 1;94(4):428-432. 10.1016/j.diii.2013.01.001
3. Ghosh SK, Biswas S, Sharma S, Chakraborty S. An anatomical study of wormian bones from the eastern part of India: is genetic influence a primary determinant of their morphogenesis? *Anatomical Science International*. 2017 Jun 1;92(3):373-382. 10.1007/s12565-016-0342-1
4. Marathe R, Yogesh A, Pandit S, Joshi M, Trivedi G. Inca - interparietal bones in neurocranium of human skulls in central India. *Journal of Neurosciences in Rural Practice*. 2010 Jan;1(1):14-16. 10.4103/0976-3147.63094
5. Bennett KA. The etiology and genetics of wormian bones. *American Journal of Physical Anthropology*. 1965 Sep;23(3):255-260. 10.1002/ajpa.1330230313
6. Goyal N, Garg A, Kumar Y. Incidence and medicolegal significance of Wormian bones in human skulls in North India region. *International Journal of Applied and Basic Medical Research*. 2019 Jul;9(3):165-168. 10.4103/ijabmr.IJABMR\_89\_19
7. Pryles CV, Khan AJ. Wormian bones. A marker of CNS abnormality? *American Journal of Diseases of Children*. 1979 Apr 1;133(4):380-382.
8. El-Najjar M, Dawson GL. The effect of artificial cranial deformation on the incidence of Wormian bones in the



## Wormian bones and nonsyndromic craniosynostosis: A comparative study using computed tomography

- lambdoidal suture. *American Journal of Physical Anthropology*. 1977 Jan;46(1):155-160. 10.1002/ajpa.1330460119
9. Natsis K, Piagkou M, Lazaridis N, et al. Incidence, number and topography of Wormian bones in Greek adult dry skulls. *Folia Morphologica (Warsz)*. 2019;78(2):359-370. 10.5603/FM.a2018.0078
  10. Randhawa M, Dhawan SR, Kumar S, et al. Wormian bones and dilated scalp veins in an infant with epilepsy. *Journal of Pediatric Neurosciences*. 2019 Apr 1;14(2):103-104. 10.4103/jpn.JPN\_151\_18
  11. Lee HQ, Hutson JM, Wray AC, et al. Changing epidemiology of nonsyndromic craniosynostosis and revisiting the risk factors. *Journal of Craniofacial Surgery*. 2012 Sep 1;23(5):1245-1251. 10.1097/SCS.0b013e318252d893
  12. Lajeunie E, Le Merrer M, Bonaïti-Pellie C, Marchac D, Renier D. Genetic study of nonsyndromic coronal craniosynostosis. *American Journal of Medical Genetics*. 1995 Feb 13;55(4):500-504. 10.1002/ajmg.1320550422
  13. Cornelissen M, Ottelander BD, Rizopoulos D, et al. Increase of prevalence of craniosynostosis. *Journal of Cranio-Maxillo-Facial Surgery*. 2016 Sep 1;44(9):1273-1279. 10.1016/j.jcms.2016.07.007
  14. Sanchez-Lara PA, Graham JM, Jr., Hing AV, Lee J, Cunningham M. The morphogenesis of wormian bones: a study of craniosynostosis and purposeful cranial deformation. *American Journal of Medical Genetics. Part A*. 2007 Dec 15;143A(24):3243-3251. 10.1002/ajmg.a.32073
  15. Rosset A, Spadola L, Ratib O. OsiriX: an open-source software for navigating in multidimensional DICOM images. *Journal of Digital Imaging*. 2004 Sep 1;17(3):205-216. 10.1007/s10278-004-1014-6
  16. Jeanty P, Silva SR, Turner C. Prenatal diagnosis of wormian bones. *Journal of Ultrasound in Medicine*. 2000 Dec;19(12):863-869. 10.7863/jum.2000.19.12.863
  17. Singer S, Bower C, Southall P, Goldblatt J. Craniosynostosis in Western Australia, 1980-1994: a population-based study. *American Journal of Medical Genetics*. 1999 Apr 23;83(5):382-387. 10.1002/(sici)1096-8628(19990423)83:5<382::aid-ajmg8>3.0.co;2-a
  18. Rizvi A, Iwanaga J, Oskouian RJ, Loukas M, Tubbs RS. Wormian bone of the orbit: A case report. *Cureus*. 2018;10(8):e3117. 10.7759/cureus.3117
  19. Agrawal D, Steinbok P, Cochrane DD. Pseudoclosure of anterior fontanelle by wormian bone in isolated sagittal craniosynostosis. *Pediatric Neurosurgery*. 2006;42(3):135-137. 10.1159/000091854